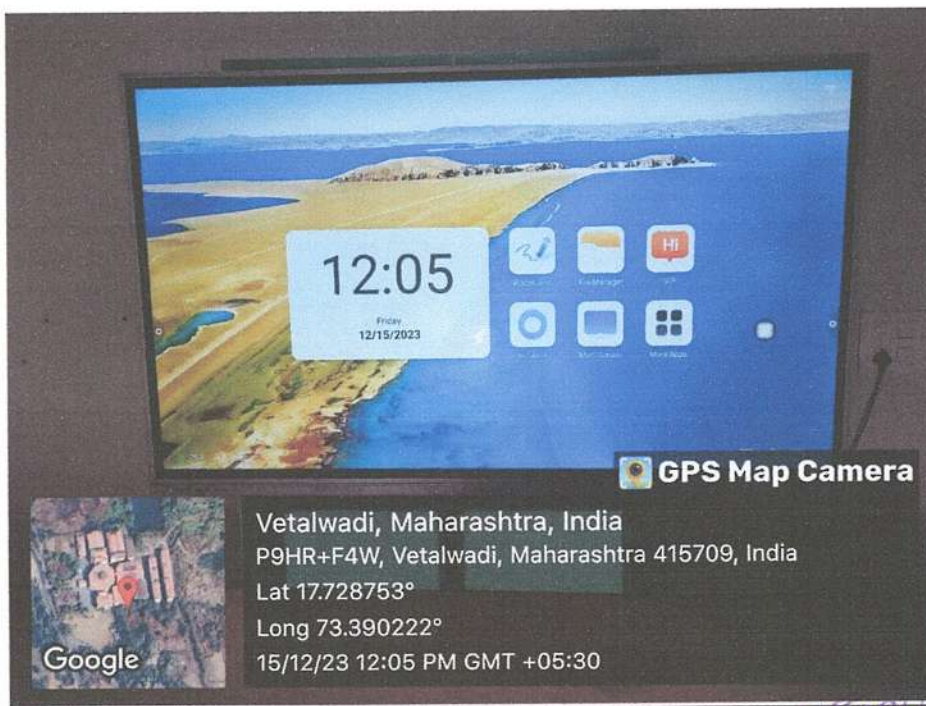





(Recognized by Dental Council of India, New Delhi & Affiliated to Maharashtra University of Health Science, Nashik)

TEACHING AND LEARNING FACILITIES

CLASSROOMS

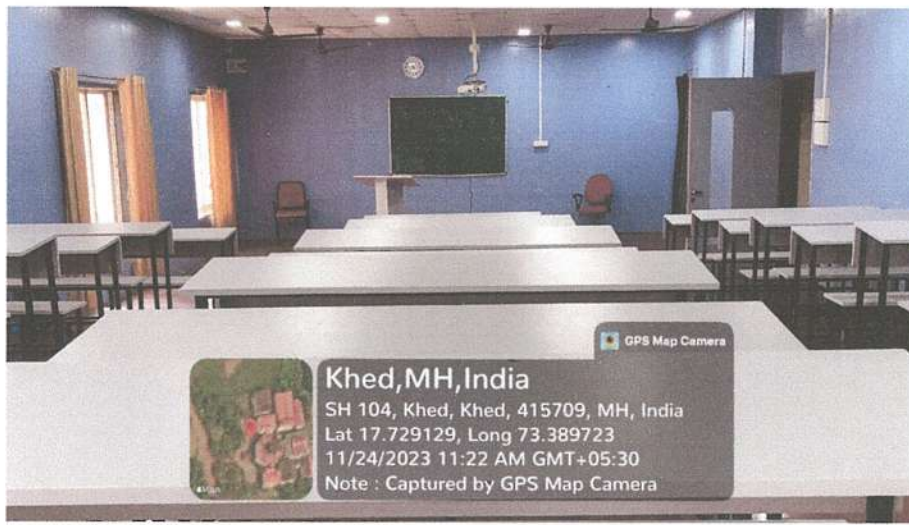


SHIVTEJ AROGYA SEVA SANSTHA'S



YOGITA DENTAL COLLEGE AND HOSPITAL

(Recognized by Dental Council of India, New Delhi & Affiliated to Maharashtra University of Health Science, Nashik)




SHIVTEJ AROGYA SEVA SANSTHA'S



YOGITA DENTAL COLLEGE AND HOSPITAL


REGD.NO.MAH/F/-1588/RATNAGIRI

(Recognized by Dental Council of India, New Delhi & Affiliated to Maharashtra University of Health Science, Nashik)



Khed, MH, India
SH 104, Khed, Khed, 415709,
Lat 17.729088, Long 73.389633
08/01/2022 01:44 PM

Smart board



Khed, MH, India
SH 104, Khed, Khed, 415709,
Lat 17.729109, Long 73.389508
08/01/2022 01:43 PM

Smart board

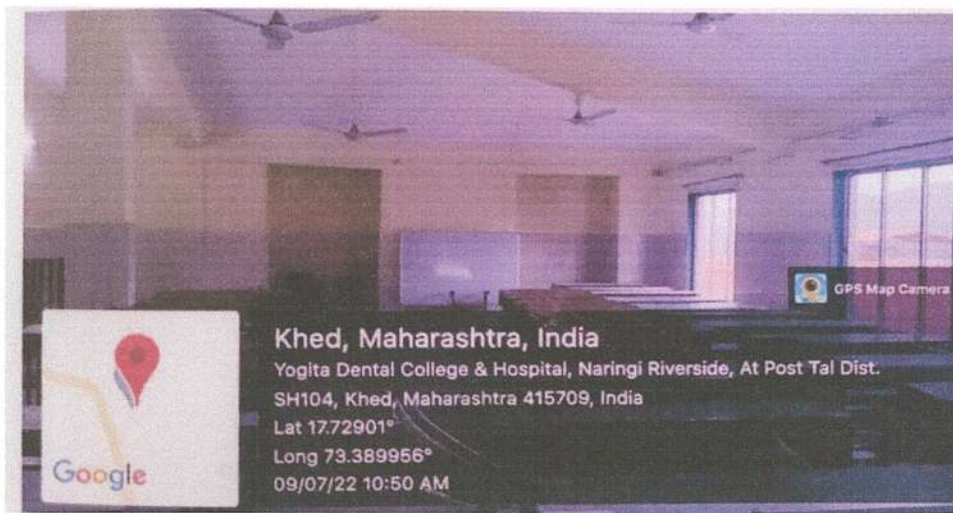
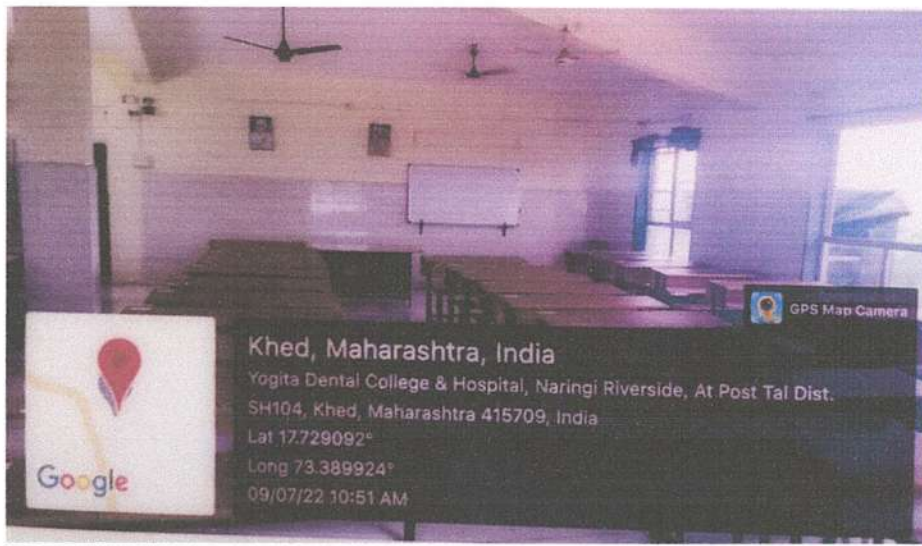
SHIVTEJ AROGYA SEVA SANSTHA'S



YOGITA DENTAL COLLEGE AND HOSPITAL

(Recognized by Dental Council of India, New Delhi & Affiliated to Maharashtra University of Health Science, Nashik)





(Recognized by Dental Council of India, New Delhi & Affiliated to Maharashtra University of Health Science, Nashik)

SEMINAR HALLS

Department of Pediatric & Preventive Dentistry





(Recognized by Dental Council of India, New Delhi & Affiliated to Maharashtra University of Health Science, Nashik)

Department Of Orthodontics





(Recognized by Dental Council of India, New Delhi & Affiliated to Maharashtra University of Health Science, Nashik)

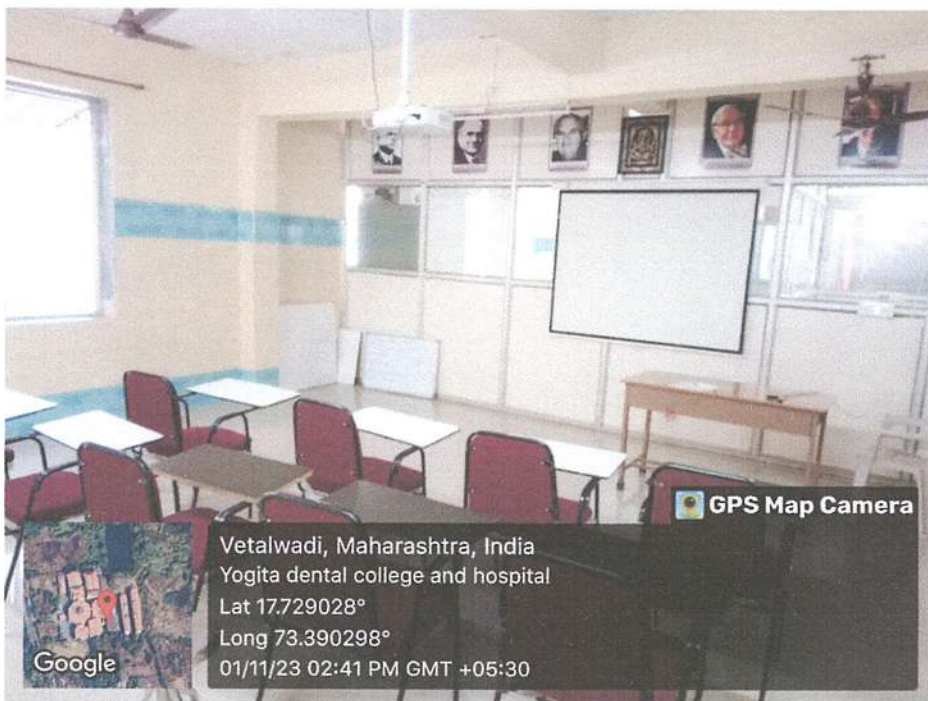Department of Prosthodontics





(Recognized by Dental Council of India, New Delhi & Affiliated to Maharashtra University of Health Science, Nashik)


Department of Periodontics





(Recognized by Dental Council of India, New Delhi & Affiliated to Maharashtra University of Health Science, Nashik)

Department of Conservative Dentistry and Endodontics





YOGITA DENTAL COLLEGE & HOSPITAL
PRINCIPAL



(Recognized by Dental Council of India, New Delhi & Affiliated to Maharashtra University of Health Science, Nashik)

Department of Biochemistry



Vetulwadi, Maharashtra, India
Yogita dental college and hospital
Lat 17.729028°
Long 73.390298°
01/11/23 02:10 PM GMT +05:30

YOGITA DENTAL COLLEGE & HOSPITAL
PRINCIPAL
Khed Rtg. 17



(Recognized by Dental Council of India, New Delhi & Affiliated to Maharashtra University of Health Science, Nashik)

LABORATORIES

Department of General Pathology & Microbiology



Vetalwadi, Maharashtra, India
Yogita dental college and hospital
Lat 17.729028°
Long 73.390298°
01/11/23 01:54 PM GMT +05:30



Vetalwadi, Maharashtra, India
Yogita dental college and hospital
Lat 17.729028°
Long 73.390298°
01/11/23 01:52 PM GMT +05:30





(Recognized by Dental Council of India, New Delhi & Affiliated to Maharashtra University of Health Science, Nashik)

Department of Prosthodontics



YOGITA DENTAL COLLEGE & HOSPITAL
PRINCIPAL
Khed, Dist. Nashik, Maharashtra



(Recognized by Dental Council of India, New Delhi & Affiliated to Maharashtra University of Health Science, Nashik)


Pre-clinical Prosthodontics





(Recognized by Dental Council of India, New Delhi & Affiliated to Maharashtra University of Health Science, Nashik)

Pre-clinical Conservative





(Recognized by Dental Council of India, New Delhi & Affiliated to Maharashtra University of Health Science, Nashik)

ORTHODONTICS AND DENTOFACIAL ORTHOPAEDICS

Vetalwadi, Maharashtra, India
Yogita dental college and hospital
Lat 17.729028°
Long 73.390298°
01/11/23 02:48 PM GMT +05:30

Vetalwadi, Maharashtra, India
Yogita dental college and hospital
Lat 17.729028°
Long 73.390298°
01/11/23 02:48 PM GMT +05:30





(Recognized by Dental Council of India, New Delhi & Affiliated to Maharashtra University of Health Science, Nashik)

PERIODONTOLOGY

INFLUENCE OF SYSTEMIC DISEASES ON PERIODONTIUM

DIABETES MELLITUS: Enlarged gingiva, acute or subacute gingival pulp, frequent abscess formation, Periodontitis and loosened teeth, deep periodontal pockets, greater loss of attachment.

Causes:

1. Bacterial Pathogens: ↑ glucose in gingival fluid and blood → change in environment of the microflora, qualitative changes in bacteria.
2. Polysphosphatase Leukocyte Function: Deficiency → impaired chemotaxis, defective phagocytosis or impaired adhesion.
3. Altered Collagen Metabolism: ↓ Collagenase activity & ↓ collagen synthesis, adversely affects synthesis, maturation, maintenance of collagen & extracellular matrix → accumulated glycogen and products (AGE's). It will make collagen less soluble.

OBESITY: ↑ in severity & progressive ↓ in Thymocyte response.

Periodontitis: bacterial plaque → accentuates gingival response. More severe in 8th month ↓ in 9th month. Marginal and interdental → height to bluish red, cauliflower like appearance → tendency to bleed.

Hyperlipidemia: Also known as systemic granuloma. It is highly vascular tumor like mass most commonly seen on the anterior part of the maxilla. It also shows increase no. of P. Intermedia.

ANEMIA:

1. ↓ in the number of erythrocytes and amount of hemoglobin. It shows pallor of the gingiva and oral mucosa, generalized atrophy of the jaw.
2. Red, smooth & shiny tongue → atrophy of the papilla.
3. Delayed healing of the gingival wound after surgical intervention.

NUTRITIONAL INFLUENCE:

Vitamin C:

1. Low level affects metabolism of collagen within periodontium, affecting tissue regeneration & repair itself.
2. Interferes with bone formation → loss of periodontal bone.
3. Does not maintain the epithelium's barrier to bacterial products.
4. ↑ in vit C enhances the chemotactic & migratory action of leucocytes without affecting their phagocytic activity.
5. Normal level → maintain the integrity of periodontal microvasculature: vascular response to bacterial plaque & wound healing.
6. Depletion of vit C → ↑ the pathogenicity of the bacteria in the plaque.

Vitamin B12: Gingivitis, glossitis, glossodynia, angular cheilitis & inflammation of the sulley oral mucosa.

1. Thiamin: heart level → hyperosmolarity, mucosa cracks on buccal mucosa, tongue, palate & erosion of oral mucosa.
2. Riboflavin: glossitis, angular cheilitis, subconjunctivitis, vasculitis, keratitis.
3. Nicotin: pellagra → glossitis, gingivitis & generalized stomatitis, accelerating ulcerative gingivitis.
4. Folate acid: atrophy of the gingiva, PDL & alveolar bone without inflammation.

IMMUNE DEFICIENCY: PMN are 1st line of defence → critical role in bacterial infection. Genetic disorders → ↓ in number & function of neutrophils → periodontal destruction.

- 1) Neutropenia, 2) Agammaglobulin, 3) Chediak-Higashi Syndrome, 4) Lazy Leukocyte Syndrome, 5) Leukocyte Adhesion Deficiency, 6) Papillon-Lévy Syndrome.

DEPARTMENT OF PERIODONTOLOGY

GPS Map Camera

Vetalwadi, Maharashtra, India
Yogita dental college and hospital
Lat 17.729028°
Long 73.390298°
01/11/23 02:46 PM GMT +05:30

Google

GPS Map Camera

Vetalwadi, Maharashtra, India
Yogita dental college and hospital
Lat 17.729028°
Long 73.390298°
01/11/23 02:45 PM GMT +05:30

Google



SHIVTEJ AROGYA SEVA SANSTHA'S



YOGITA DENTAL COLLEGE AND HOSPITAL

(Recognized by Dental Council of India, New Delhi & Affiliated to Maharashtra University of Health Science, Nashik)





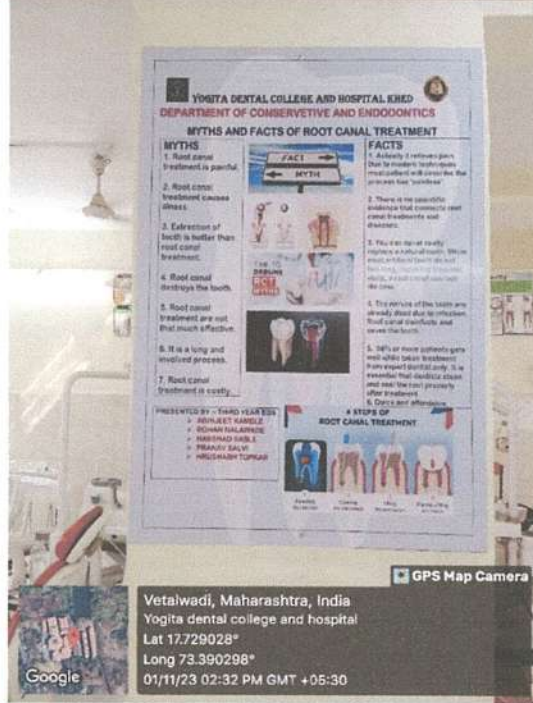
(Recognized by Dental Council of India, New Delhi & Affiliated to Maharashtra University of Health Science, Nashik)

CONSERVATIVE DENTISTRY AND ENDODONTICS



Vetalwadi, Maharashtra, India
Yogita dental college and hospital
Lat 17.729028°
Long 73.390298°
01/11/23 02:37 PM GMT +05:30

Google



Vetalwadi, Maharashtra, India
Yogita dental college and hospital
Lat 17.729028°
Long 73.390298°
01/11/23 02:32 PM GMT +05:30

Google



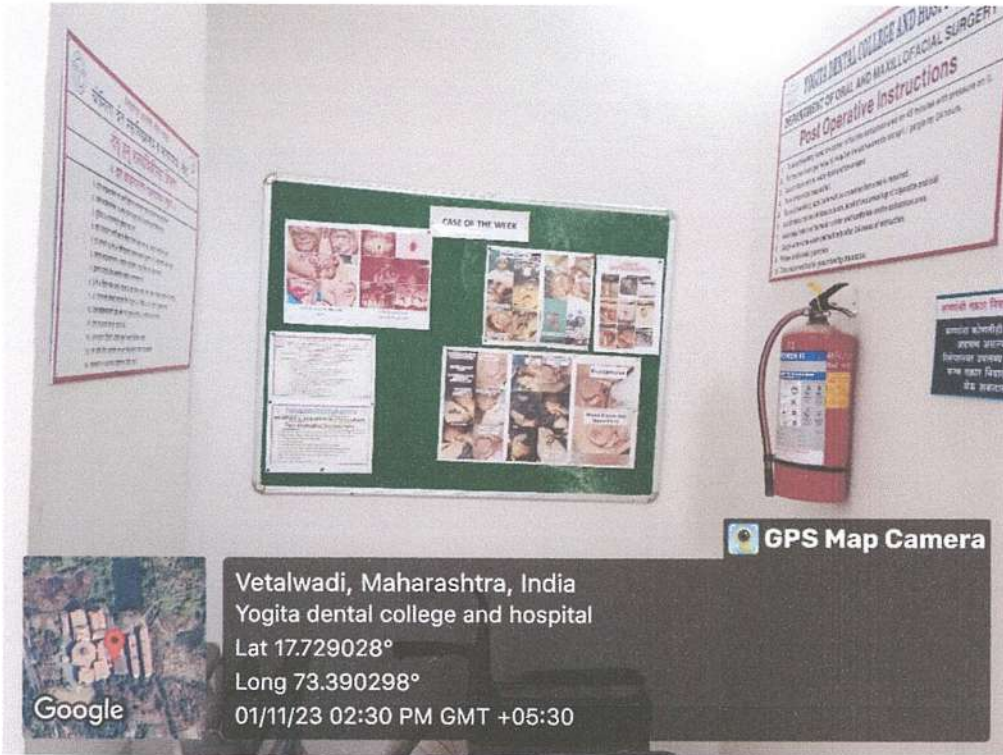SHIVTEJ AROGYA SEVA SANSTHA'S



YOGITA DENTAL COLLEGE AND HOSPITAL

(Recognized by Dental Council of India, New Delhi & Affiliated to Maharashtra University of Health Science, Nashik)

ORAL SURGERY

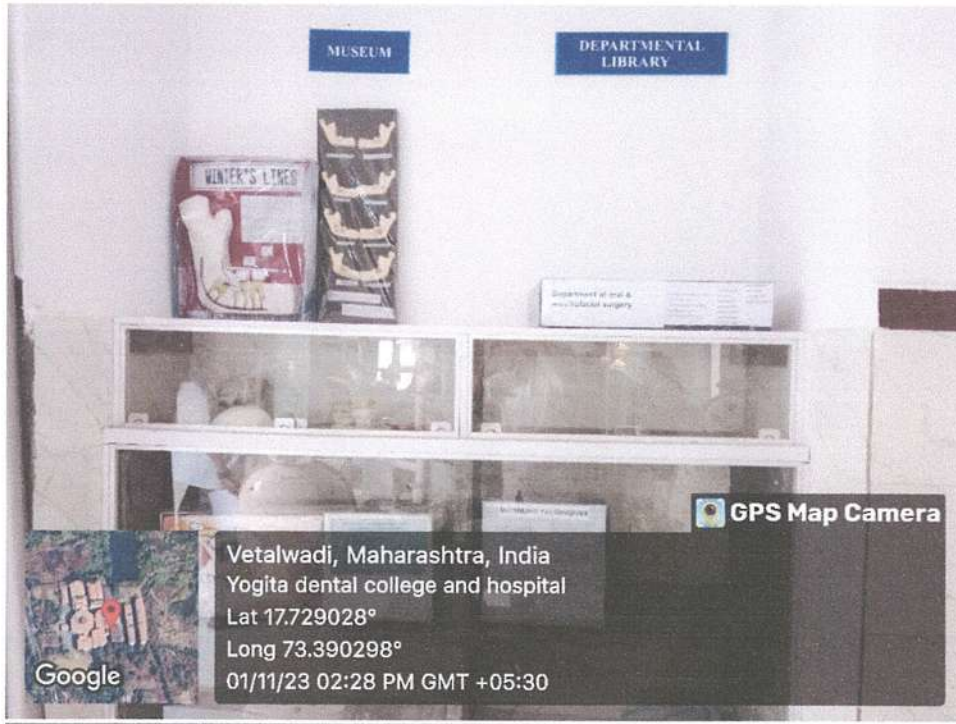


SHIVTEJ AROGYA SEVA SANSTHA'S



YOGITA DENTAL COLLEGE AND HOSPITAL

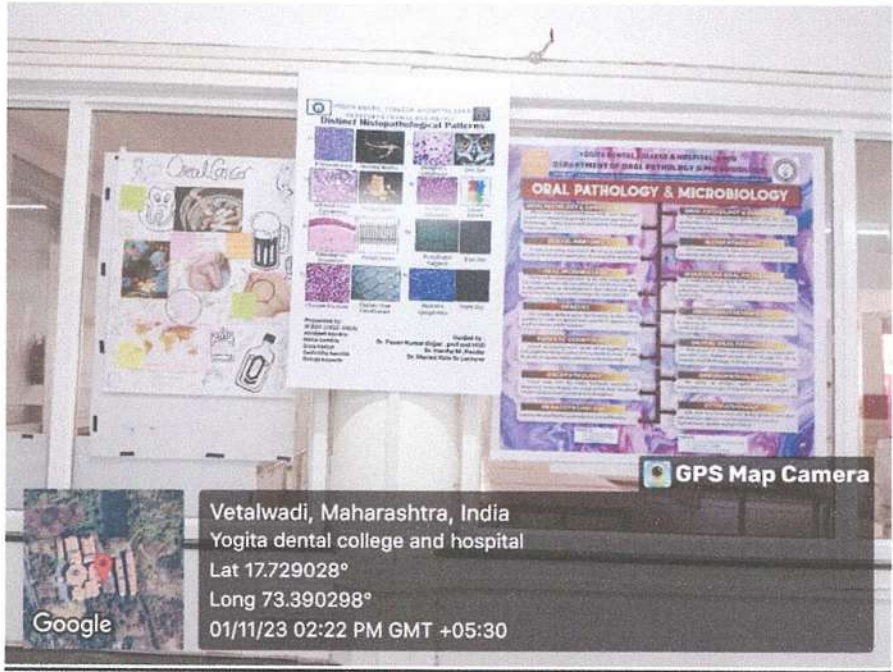(Recognized by Dental Council of India, New Delhi & Affiliated to Maharashtra University of Health Science, Nashik)





(Recognized by Dental Council of India, New Delhi & Affiliated to Maharashtra University of Health Science, Nashik)

ORAL PATHOLOGY AND MICROBIOLOGY



YOGITA DENTAL COLLEGE & HOSPITAL
PRINCIPAL
Khed Rtg. 19



(Recognized by Dental Council of India, New Delhi & Affiliated to Maharashtra University of Health Science, Nashik)

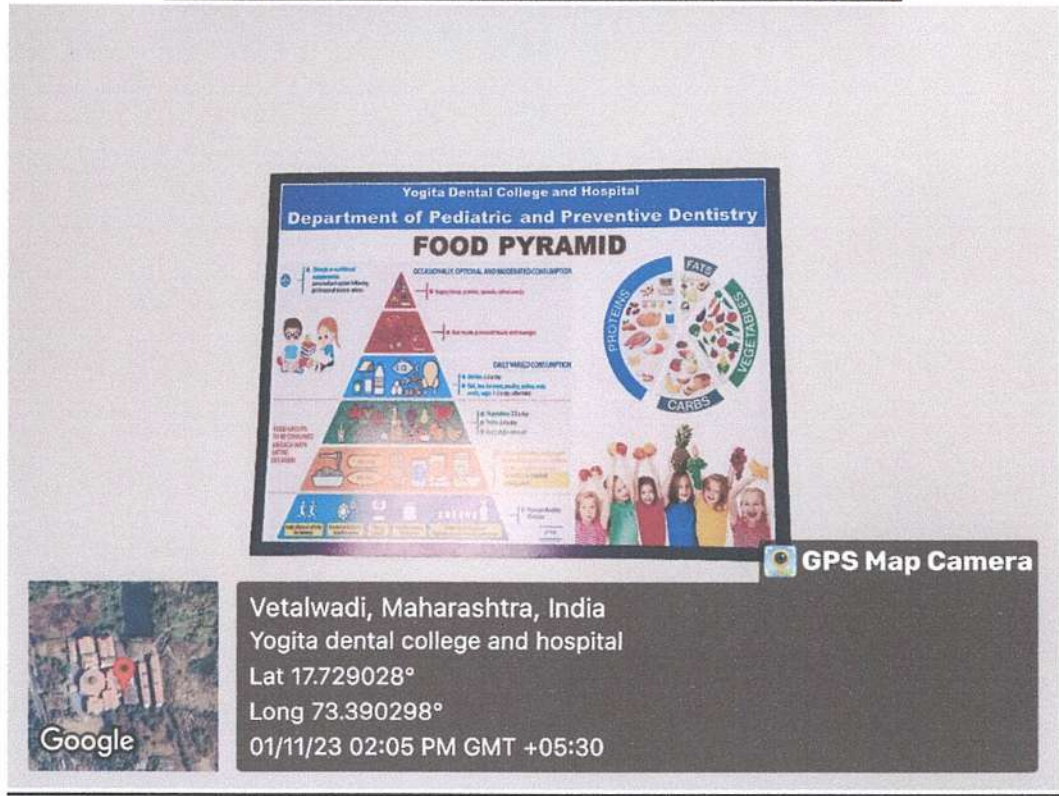PROSTHODONTICS AND CROWN AND BRIDGE





(Recognized by Dental Council of India, New Delhi & Affiliated to Maharashtra University of Health Science, Nashik)

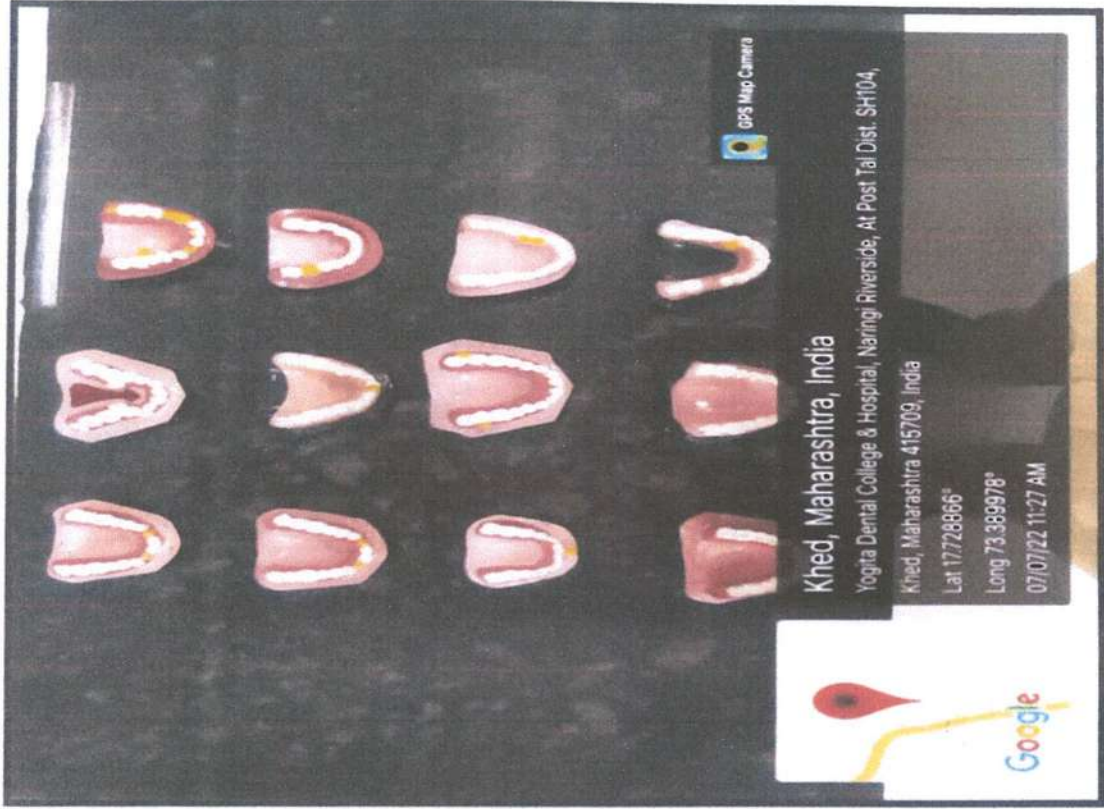
PEDODONTICS AND PREVENTIVE DENTISTRY



YOGITA DENTAL COLLEGE & HOSPITAL
PRINCIPAL
KHEDE RIG.

Tooth Specimens

CAST SPECIMENS



TRUE COPY
[Signature]
Dean, Principal
Yogita Dental College
Khed, Ratnagiri.

Wax Models

MUSEUM



TRUE COPY
Dean / Principal
Yogita Dental College
Kheda, Ra...

SHIVTEJ AROGYA SEVA SANSTHA'S

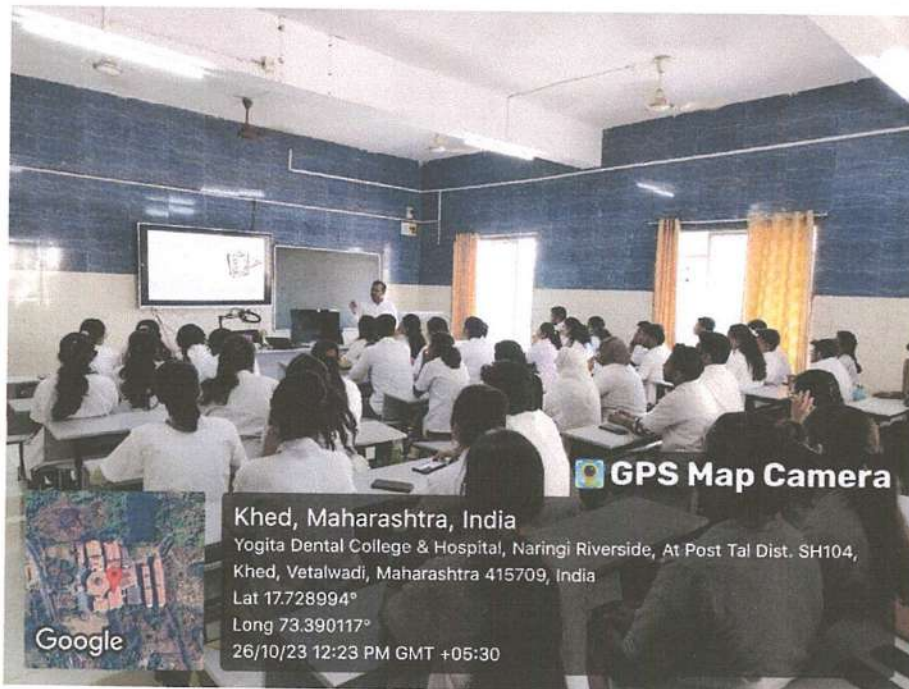
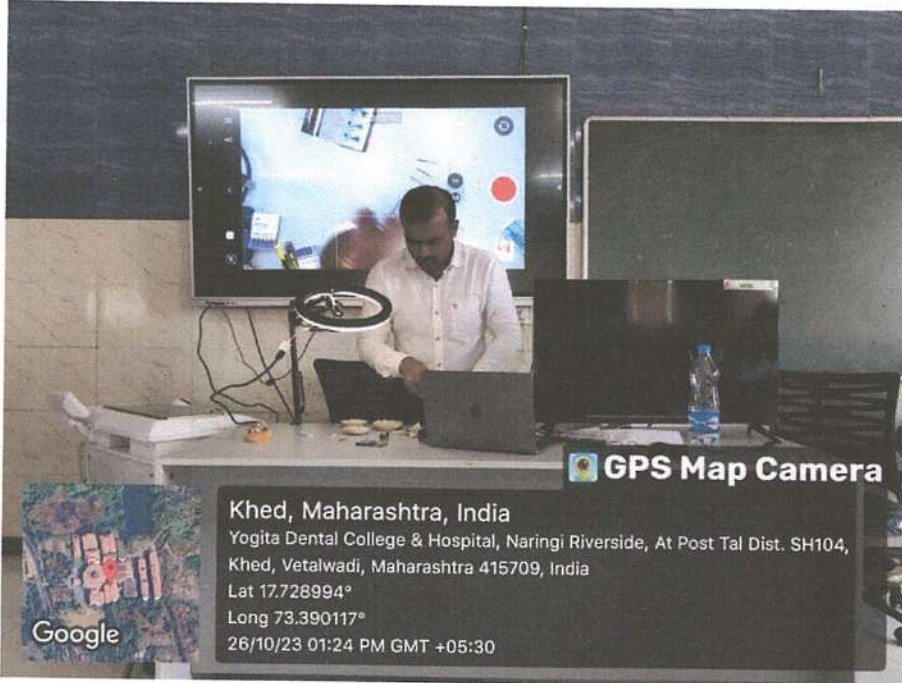


YOGITA DENTAL COLLEGE AND HOSPITAL

REGD.NO.MAH F/-1588/RATNAGIRI

(Recognized by Dental Council of India, New Delhi & Affiliated to Maharashtra University of Health Science, Nashik)

DIRECT PROJECTION AND SIMULATED LEARNING



SHIVTEJ AROGYA SEVA SANSTHA'S



YOGITA DENTAL COLLEGE AND HOSPITAL

REGD.NO.MAH/F/-1588/RATNAGIRI

(Recognized by Dental Council of India, New Delhi & Affiliated to Maharashtra University of Health Science, Nashik)

