



REGD.NO.MAH/F/-1588/RATNAGIRI

(Recognized by Dental Council of India, New Delhi & Affiliated to Maharashtra University of Health Science, Nashik)

Ref.No: YDCH/2407/1139/2022

Date: 03/08/2022

**DEPARTMENT OF PUBLIC HEALTH DENTISTRY**

**PHC POSTING SCHEDULE**

**2022-2023**

Yogita Dental College & Hospital, Khed is attached with 100 bedded Sub-district Hospital at Kalambani situated 8 km from the institute.

A dental satellite centre equipped with dental chair, sterilization unit, required consumable & non-consumable material has been established at the hospital where **students (UGs/Interns) of Yogita Dental College posted in Public Health Dentistry department are scheduled to report daily on rotation basis to provide comprehensive dental care.**

HOD

Dept. of PHD

Principal

YDCH, KHED

CEO

YDCH, KHED



TRUE COPY

Deen: Principal  
Yogita Dental College  
Khed, Ratnagiri

# SHIVTEJ AROGYA SEVA SANSTHA'S



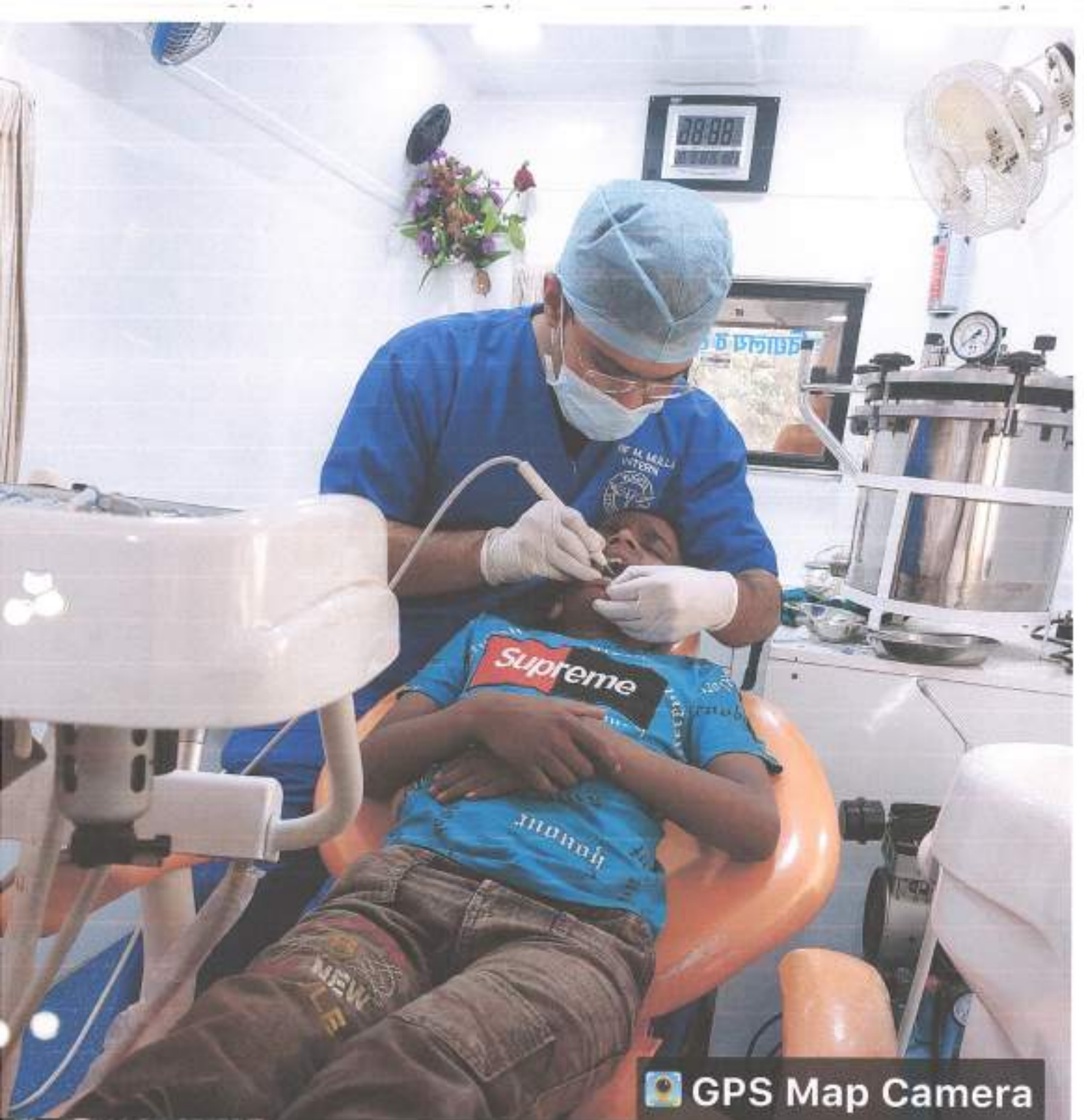## YOGITA DENTAL COLLEGE AND HOSPITAL


REGD.NO.MAH/F/-1588/RATNAGIRI

(Recognized by Dental Council of India, New Delhi & Affiliated to Maharashtra University of Health Science, Nashik)

### RURAL HEALTH CENTER PHOTOS





 GPS Map Camera

**Ratnagiri, Maharashtra, India**

Shop No 4 and, Varcha fagarvatar, Boarding Rd,  
Sanmitra Nagar, Ratnagiri, Maharashtra 415612, India

Lat 16.996864°

Long 73.300365°

14/01/23 01:49 PM GMT +05:30



Google

TRUE COPY  
Dean FPrincipal  
Yogita Dental College  
Kheu, Ratnagiri.

# SHIVTEJ AROGYA SEVA SANSTHA'S

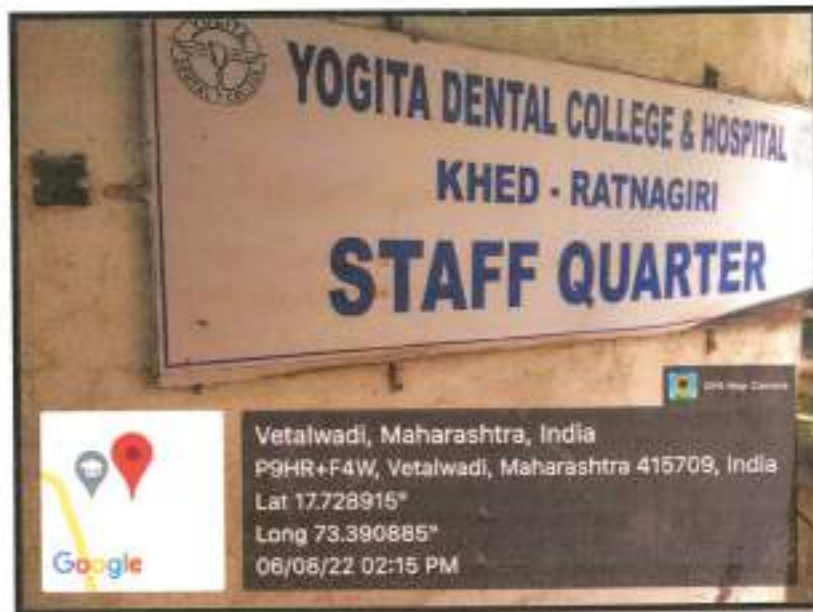


## YOGITA DENTAL COLLEGE AND HOSPITAL

REGD.NO.MAH/F/-1588/RATNAGIRI

(Recognized by Dental Council of India, New Delhi & Affiliated to Maharashtra University of Health Science, Nashik)

### RESIDENTIAL FACILITY FOR STUDENTS AND STAFF



# SHIVTEJ AROGYA SEVA SANSTHA'S



## YOGITA DENTAL COLLEGE AND HOSPITAL

REGD.NO.MAH/F/-1588/RATNAGIRI

(Recognized by Dental Council of India, New Delhi & Affiliated to Maharashtra University of Health Science, Nashik)



# SHIVTEJ AROGYA SEVA SANSTHA'S



## YOGITA DENTAL COLLEGE AND HOSPITAL

REGD.NO.MAH/F/-1588/RATNAGIRI

(Recognized by Dental Council of India, New Delhi & Affiliated to Maharashtra University of Health Science, Nashik)

### TO WHOM IT MAY CONCERN

This is to kindly inform you that a Mobile Dental Unit equipped with one fully functional dental chair is functioning. The Mobile Dental Van has been functioning with an aim to reach and provide essential dental care to population with limited access to health care. Attempt is made to visit various parts of the district especially the rural population, school children, children with special health care and geriatric population. Different treatment procedures like oral prophylaxis, restorations, emergency root canal opening, extraction, etc are performed.



Dr. Varsha Jadhav

DEAN

Yogita Dental College & Hospital, Khed

# SHIVTEJ AROGYA SEVA SANSTHA'S



## YOGITA DENTAL COLLEGE AND HOSPITAL

REGD.NO.MAH/F/-1588/RATNAGIRI

(Recognized by Dental Council of India, New Delhi & Affiliated to Maharashtra University of Health Science, Nashik)

### TO WHO IT MAY CONCERN

This is to kindly you that a Mobile Dental Unit is equipped with one fully functional dental chair which is functioning. The Mobile Dental Van has been functioning with an aim to reach and provide essential dental care to population with limited access to health care.

Attempt is made to visit various parts of the district especially the rural areas with limited access, school children, children with special health care needs and geriatric population.

Different treatment procedures like oral prophylaxis, restorations, emergency root canal opening, grade III extractions, etc are performed.



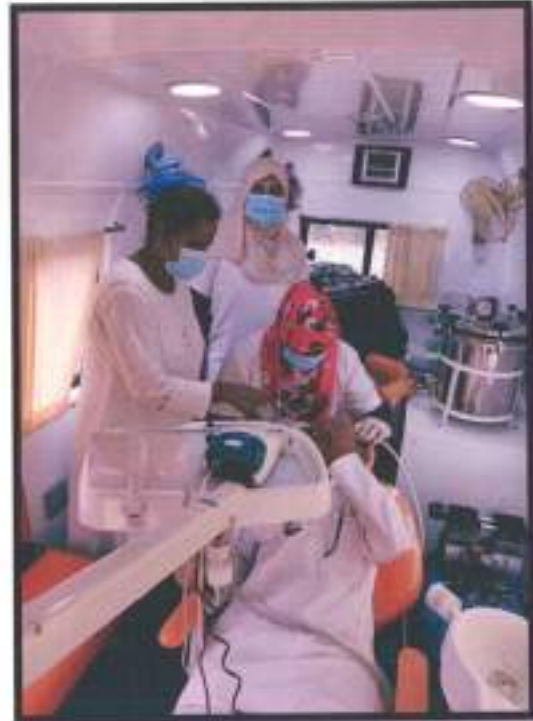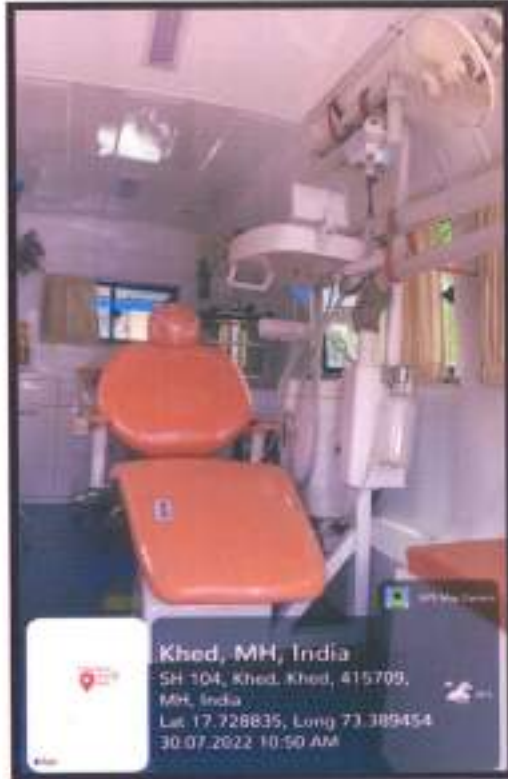
# SHIVTEJ AROGYA SEVA SANSTHA'S



## YOGITA DENTAL COLLEGE AND HOSPITAL

REGD.NO.MAH/F/-1588/RATNAGIRI

(Recognized by Dental Council of India, New Delhi & Affiliated to Maharashtra University of Health Science, Nashik)



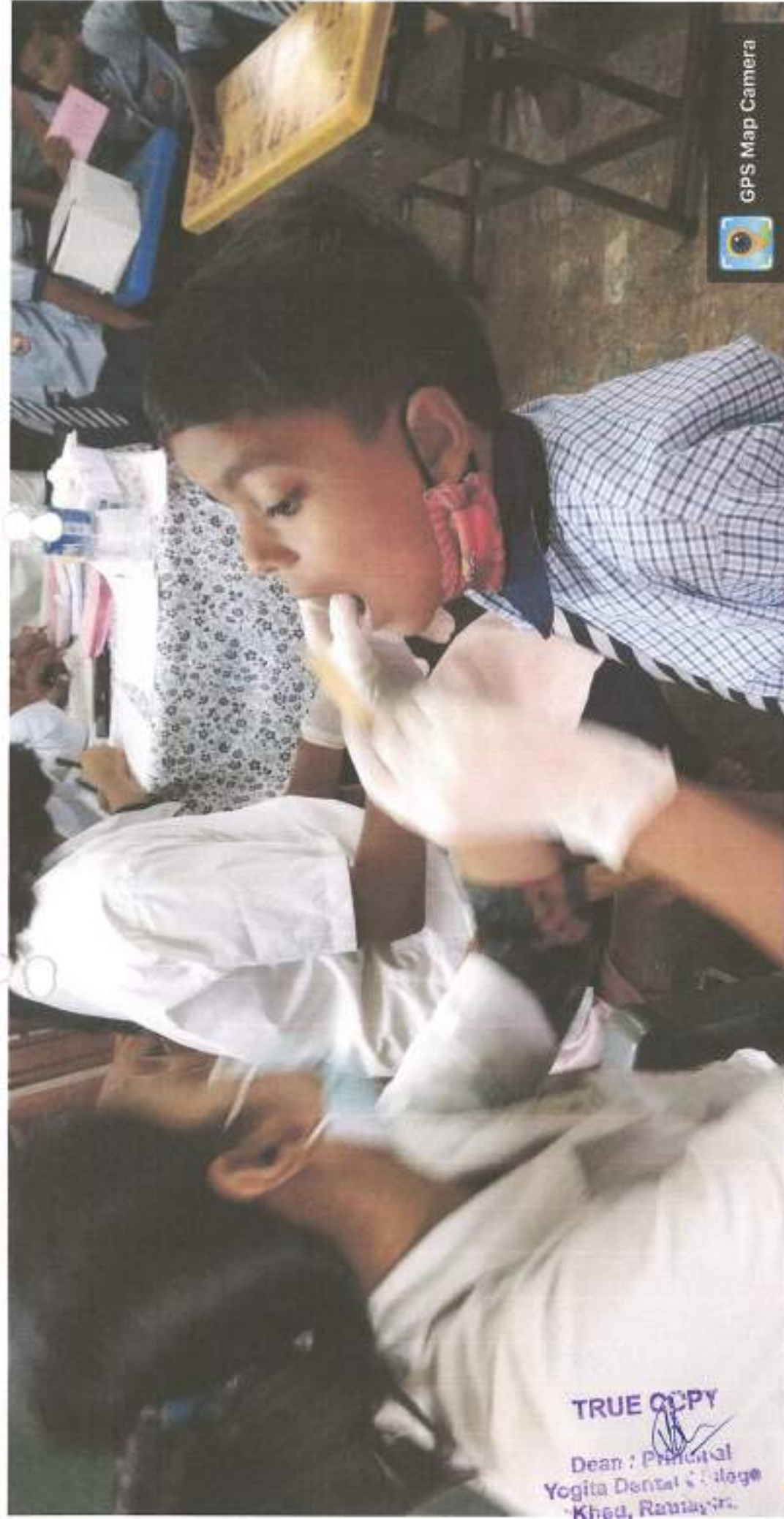DR. VARSHA JADHAV

DEAN

YOGITA DENTAL COLLEGE & HOSPITAL, KHED







TRUE COPY  
Dean : Pratik  
Yogita Dental College  
Khed, Ratnagiri.



GPS Map Camera

## Dabhol, Maharashtra, India

गंगासागर निवास, चंडिका पाखाडी, Dabhol, Maharashtra 415706,

India

Lat 17.589642°

Long 73.177536°

28/06/22 12:17 PM





GPS Map Camera

Dabhol, Maharashtra, India  
H5QG+6W4, Dabhol, Maharashtra 415706, India  
Lat 17.588269°  
Long 73.177147°  
28/06/22 12:00 PM



4



GPS Map Camera

# Dabhol, Maharashtra, India

H5QP+WVC, Dabhol, Maharashtra 415706, India

Lat 17.590066°

Long 73.187183°

01/12/22 02:31 PM GMT +05:30



Google

ग्रामपंचायत कार्यालय नातुनगर  
आपले सहर्ष स्वागत करीत आहे

शेतकऱ्यांसाठी योजना

पीएम कसूम योजनेची विविध उपाययोजना, जमाव भरती  
आणि इतर शेतकऱ्यांसाठी उपयुक्त सेवा उपलब्ध करून देणे

सामाजिक  
दंतशास्त्र  
विभाग  
COMMUNITY DENTAL CARE

GPS Map Camera

Natunagar, Maharashtra, India  
RCH3+WFR, Natunagar, Maharashtra 415640, India  
Lat 17.8295665°  
Long 73.40401°  
01/11/23 03:09 PM GMT +05:30

TRUE COPY

Dean / Principal  
Yogita Dental College  
Kheu, Ramnagar

Google



Dean : Principal  
Yogita Datta College  
Khetu, Raipur















## YOGITA DENTAL COLLEGE &amp; HOSPITAL

KHED, Dist. Ratnagiri,

Dept. of Public Health Dentistry

OPD REGISTER, ( Kalambani Hospital ) Date : 28/11/23

Sr. No.	Case No.	Patient Name	Age	Sex	Place
1.	22915	Janardan Tambir	60		Kalambani
2.	28126	Prakash Shinde	65		Kalambani
3.	<del>22559</del> 28125	Amar Chavan	36	M	Versal.
4.	28148	Ninad Chosde	45	M	Bhaste
5.	28136	Aksa Desai	33	F	Bhadgaon.
6.		Bhushan Salunke	4	M	Sukivali

TRUE COPY

Dean, Principal  
Yogita Dental College  
Khed, Ratnagiri.



## YOGITA DENTAL COLLEGE &amp; HOSPITAL

KHED, Dist. Ratnagiri,

Dept. of Public Health Dentistry

OPD REGISTER, ( Kalambani Hospital ) Date : 22/8/23

Sr. No.	Case No.	Patient Name	Age	Sex	Place
1)		Noelina Firkhe	42	F	Chichghar
2)		Sumpasa Nage	22	F	Sukhewali
3)		Mayika Wafar	SD	F	Musele
4)		Anita Kadam	52	F	Junge
5)		Mangla Jaellav	61	F	Ambaye
6)		Urishali Sakpat	35	F	Ambaye
7)		Supriya Gtag	45	F	Sukhewali
8)		Dakshata Shide	50	F	Bhadgan
9)		Tejashwini Pipre	47	F	Bhane
10)		Mamta Patne	47	F	Bhane
11)		Sonal Kadam	53	F	Ambaye

TRUE COPY

Dean / Principal  
Yogita Dental College  
Khed, Ratnagiri



## YOGITA DENTAL COLLEGE &amp; HOSPITAL


KHED, Dist. Ratnagiri,

Dept. of Public Health Dentistry

OPD REGISTER, ( Kalambani Hospital ) Date : 19/6/23

Sr. No.	Case No.	Patient Name	Age	Sex	Place
1.		Chandrakant Manjtan	65	M.	Kadambadi
2.		Minal Ghom	50	F.	Khed
3.		Pratiksha Jund	45	F	Yeral
4.		Vinod Nivakte	42	M	Khed.
5.		Vikki Ambrd	28	M	Kadambadi
6.		Prakash Gawade.	34	M	Kadambadi

TRUE COPY

Dean :   
 Yogita Dental College  
 Khed, Ratnagiri.





# Shivtej Arogya Seva Sanstha YOGITA DENTAL COLLEGE & HOSPITAL

KHED, Dist. Ratnagiri,

Dept. of Public Health Dentistry

OPD REGISTER

Date: 21/10/23

Sr. No.	Case No.	Patient Name	Age	Sex	Phone No.	Treatment	Dr. Name
1.	19317	Rupali Sarkar Pt has habit of mushers since 15-20 yrs 1-2 times a day. No lesion.	56	F			<u>Kamal</u> <u>Futim</u>
2.	19321	Suresh Damodkar Pt has a habit of chewing tobacco twice a day since 6 yrs. Greyish white patch seen in lower vestibule in lower left region Suggestive of tobacco pouch keratosis.	46	M			

TRUE COPY

Shivtej Arogya Seva Sanstha  
**YOGITA DENTAL COLLEGE & HOSPITAL**

KHED, Dist. Ratnagiri.

Dept. of Public Health Dentistry

OPD REGISTER

Date: 17/11/23.

Sr. No.	Case No.	Patient Name	Age	Sex	Phone No.	Treatment	Dr. Name
1.		Satharam Shinde	52	M			
		Pt has a habit of chewing gutkha for twice a day since 5 years. Grayish white patch seen in lower right vestibular region. suggestive of tobacco pouch keratosis.					
2.		Vivek Patil	28	M.			
		Pt. has a habit of smoking cigarette for thrice a day since 8 years.					

TRUE COPY  
Dean : Principal  
Yogita Dental College  
Khed, Ratnagiri.

# Shivtej Arogya Seva Sanstha YOGITA DENTAL COLLEGE & HOSPITAL

KHED, Dist. Ratnagiri,  
Dept. of Public Health Dentistry  
OPD REGISTER

Date: 10/11/23.

Sr. No.	Case No.	Patient Name	Age	Sex	Phone No.	Treatment	Dr. Name
1.	10	Subhadra Gaurse Pt has a habit of chewing Mishri thrice a day since 10 years. Grayish white patch seen on lower vestibular region which is non-scrapable. Suggestive of tobacco pouch keratosis.	60	F			
2.		Chandrabant Saigan Pt has a habit of chewing tobacco thrice a day since 20 years. Grayish brown patch seen in lower left vestibular region which is non-scrapable. Suggestive of oral submucous fibrosis.	60	M.			

TRUE COPY  
Dean / Principal  
Yogita Dental College  
Khed, Ratnagiri.

# Shivtej Arogya Seva Sanstha YOGITA DENTAL COLLEGE & HOSPITAL

KHED, Dist. Ratnagiri,

Dept. of Public Health Dentistry

OPD REGISTER

Date: 10/11/23.

Sr. No.	Case No.	Patient Name	Age	Sex	Phone No.	Treatment	Dr. Name
1.	10	Subhadra Gaurse	60	F			
		Pt has a habit of chewing kishki thrice a day since 10 years. Grayish white patch seen on lower vestibular region which is non-scrapable. Suggestive of tobacco pouch keratosis.					
2.		Chandrabant Saigao	60	M.			
		Pt has a habit of chewing tobacco thrice a day since 20 years. Grayish brown patch seen in lower left vestibular region which is non-scrapable. Suggestive of oral submucous fibrosis.					

TRUE COPY

Dean / Principal  
Yogita Dental College  
Khed, Ratnagiri.

## YOGITA DENTAL COLLEGE &amp; HOSPITAL

KHED, Dist. Ratnagiri,

Dept. of Public Health Dentistry

OPD REGISTER

Date: 12/12/23

Sr. No.	Case No.	Patient Name	Age	Sex	Phone No.	Treatment	Dr. Name
	24529	Santosh Kadam pt. has habit of tobacco chewing. Three times day. since 15 years. No habit of	54	M		stoppage of habit	Mahadik
	24539	Sharavani Kalamkar pt. has habit of Smoking. PID - Tobacco pouch keratosis.					
	24539	Sharavani Kalamkar pt. has habit of mishri. since 10 years. Twice a day. No habit of smoking. PID: Tobacco induced melanosis.				stoppage of habit	Prithvi

TRUE COPY

Dean: Prithvi  
Yogita Dental College  
Khed, Ratnagiri.

