DEVELOPMENTAL DISTURBANCES

Dr manasi kale

FACIAL HEMIHYPERTROPHY (HYPERPLASIA)

- Hemihyperplasia is a rare developmental anomaly characterized by asymmetric overgrowth of one or more body parts.
- Although the condition is known more commonly as hemihypertrophy, it actually represents a hyperplasia of the tissues rather than a hypertrophy.
- Hemihyperplasia can be an isolated finding, but it also may be associated with a variety of malformation syndromes
- Almost all cases of isolated hemihyperplasia are sporadic

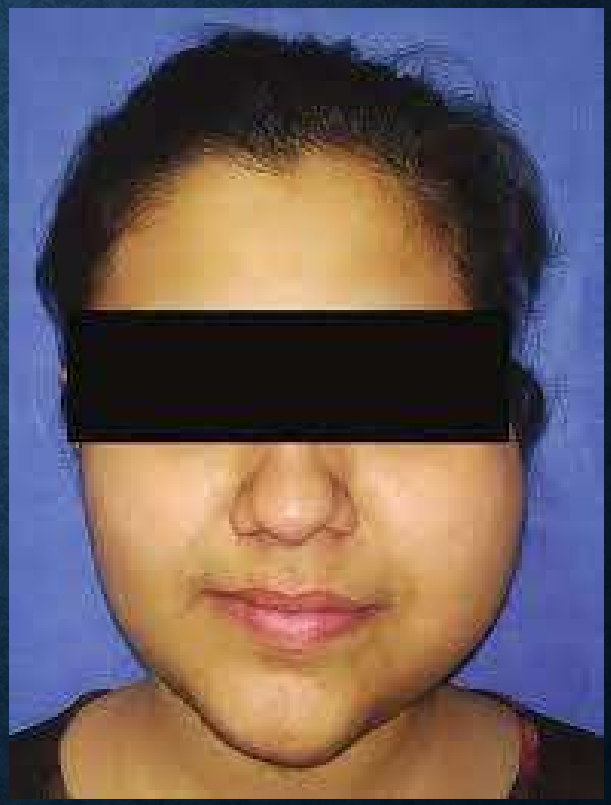

Some malformation syndromes associated with hemihyperplasia

- Beckwith-Wiedemann syndrome
- Neurofi bromatosis
- Klippel-Trenaunay-Weber syndrome
- Proteus syndrome
- McCune-Albright syndrome
- Epidermal nevus syndrome

- The cause is unknown, but the condition has been variously ascribed to vascular or lymphatic abnormalities; CNS disturbances; and chromosomal abnormalities.

Clinical Features

- Enlargement which is confined to one side of the body, unilateral macroglossia and premature development, and eruption as well as an increased size of dentition.
- Females are affected somewhat more frequently than males (63% versus 37%)
- There is an almost equal involvement of the right and left sides.

ORAL MANIFESTATIONS

- The dentition of the hypertrophic side is abnormal in three respects: crown size, root size and shape, and rate of development.
- The permanent teeth on the affected side are often enlarged, although not exceeding a 50% increase in size.
- This enlargement may involve any tooth, but seems to occur most frequently in the cuspid, premolars, and first molar. The roots of the teeth are sometimes proportionately enlarged but may be short.
- Coincident to this phenomenon is premature shedding of the deciduous teeth.

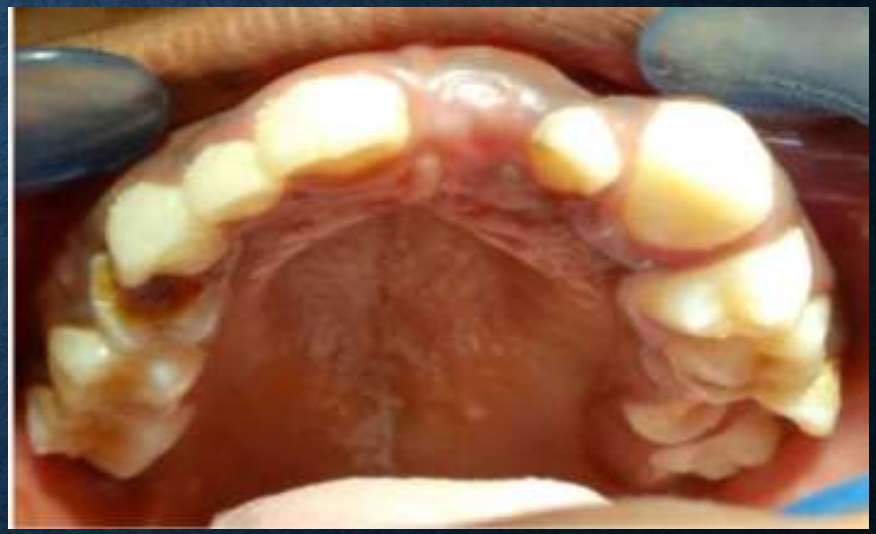

- The tongue is commonly involved by the hemihypertrophy and may show a bizarre picture of enlargement of lingual papillae in addition to the general unilateral enlargement and contralateral displacement.
- In addition, the buccal mucosa frequently appears velvety and may seem to hang in soft, pendulous folds on the affected side.

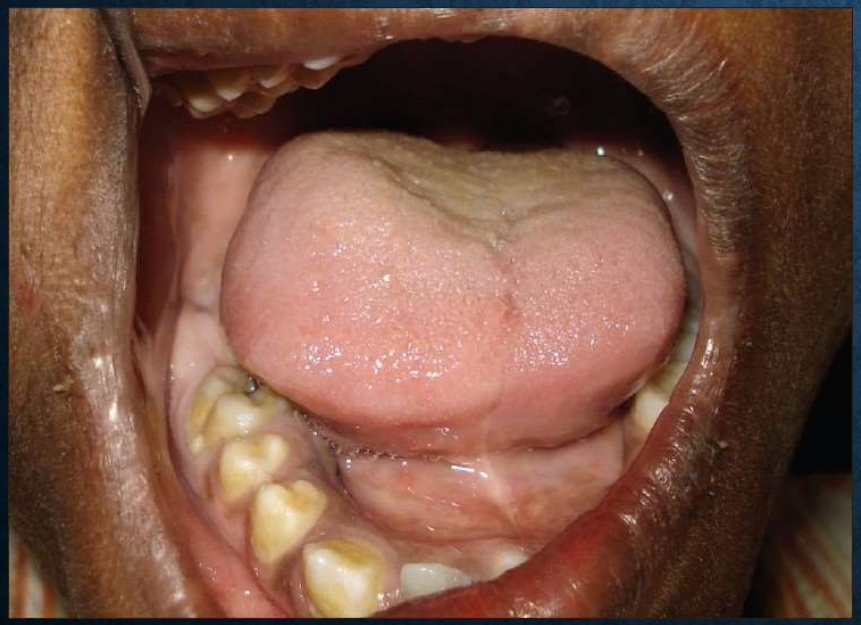

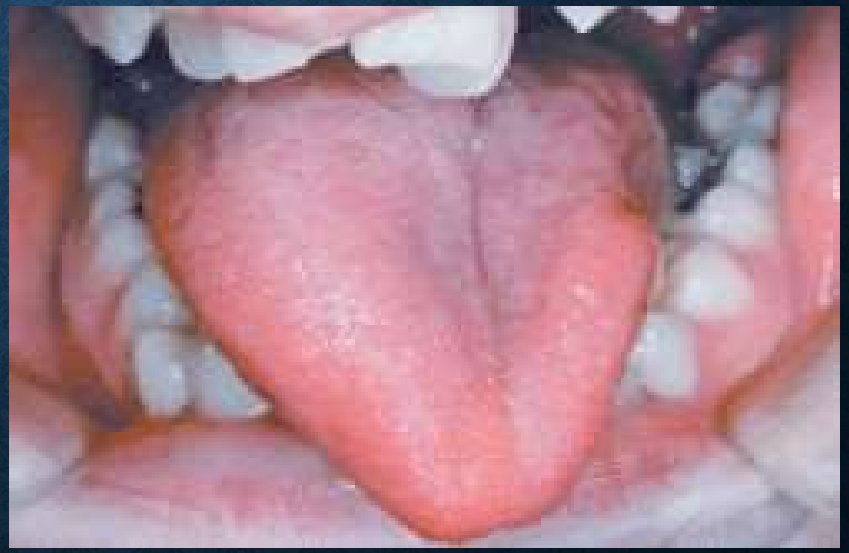

Treatment and Prognosis

- Cosmetic surgery is advised after cessation of growth.

Differential Diagnosis

Neurofibromatosis and fibrous dysplasia of the jaws may give the clinical appearance of facial hemihypertrophy, but these can usually be differentiated readily by the lack of effect on tooth size and rate of eruption

FACIAL HEMIATROPHY (PARRY-ROMBERG SYNDROME, ROMBERG-PARRY SYNDROME, PROGRESSIVE FACIAL HEMIATROPHY, PROGRESSIVE HEMIFACIAL ATROPHY)

- First reported by Romberg in 1846
- Consists of slowly progressive atrophy of the soft tissues of essentially half the face, which is characterized by progressive wasting of subcutaneous fat, sometimes accompanied by atrophy of skin, cartilage, bone and muscle.
- It is accompanied usually by contralateral epilepsy, trigeminal neuralgia, and changes in the eyes and hair.
- The presence of antinuclear antibodies in his serum suggested that the Parry-Romberg syndrome may be a form of localized scleroderma.
- The majority of cases are sporadic with no definite inheritance being proven in the literature.

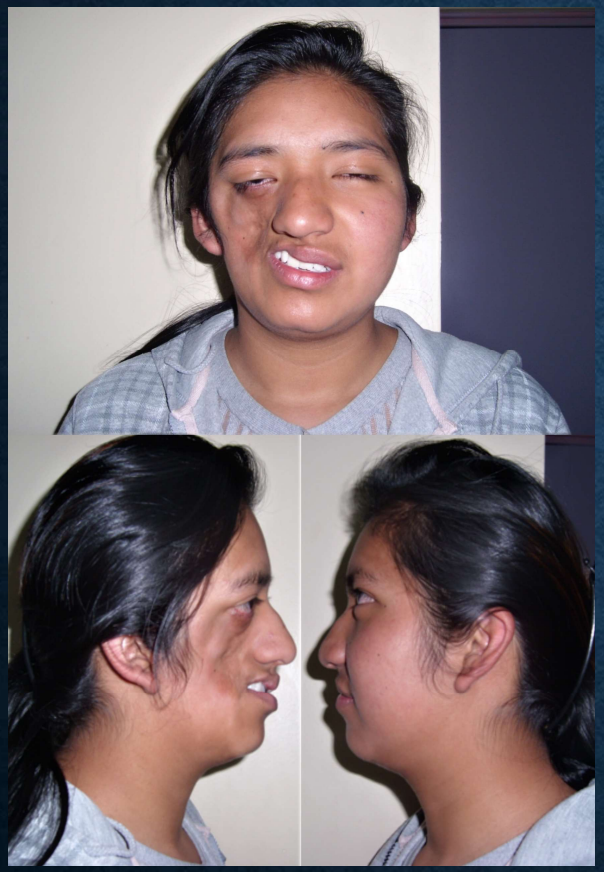


Law
PLASTIC SURGERY
LAW PLASTIC SURGERY

ETIOLOGY

- Cerebral disturbance leading to increased and unregulated activity of sympathetic nervous system, which in turn produced the localized atrophy through its trophic functions conducted by way of sensory trunks of the trigeminal nerve.
- Other workers suggested extraction of teeth, local trauma, infection and genetic factors could also be a cause.

CLINICAL FEATURES

- The most common early sign is a painless cleft, the ‘coup de sabre,’ near the midline of the face or forehead. This marks the boundary between normal and atrophic tissue.
- A bluish hue may appear in the skin overlying atrophic fat.
- The affected area extends progressively with the atrophy of the skin, subcutaneous tissue, muscles, bones, cartilages, alveolar bone and soft palate on that side of the face.
- In addition to facial wasting that may include the ipsilateral salivary glands and hemiatrophy of the tongue, unilateral involvement of the ear, larynx, esophagus, diaphragm, kidney and brain have been reported.

- Neurological disorders are found in 15% of patients, while ocular findings occur in 10–40%, the most common being enophthalmos.
- Rarely, one half of the body may be affected. This condition may be accompanied by pigmentation disorders, vitiligo, pigmented facial nevi, contralateral epilepsy, contralateral trigeminal neuralgia and ocular complications.
- The disease occurs more frequently in women; female to male ratio is 3 : 2.
- It has a slight predilection for the left side and appears in the first or second decades of life.

ORAL MANIFESTATIONS

- Incomplete root formation, delayed eruption and severe facial asymmetry, resulting in facial deformation and difficulty with mastication.
- Hemiatrophy of the lips and the tongue is reported, as are dental effects.
- Eruption of teeth on the affected side may also be retarded.

Treatment and Prognosis: surgical cosmetic correction


ANY
QUESTIONS
?

ABNORMALITIES OF DENTAL ARCH RELATIONS

- A great many different types of malocclusion exist, and many classifications have been evolved in an attempt to unify methods of treatment.
- The classification of Angle, proposed in 1899, is the most universally known and used.

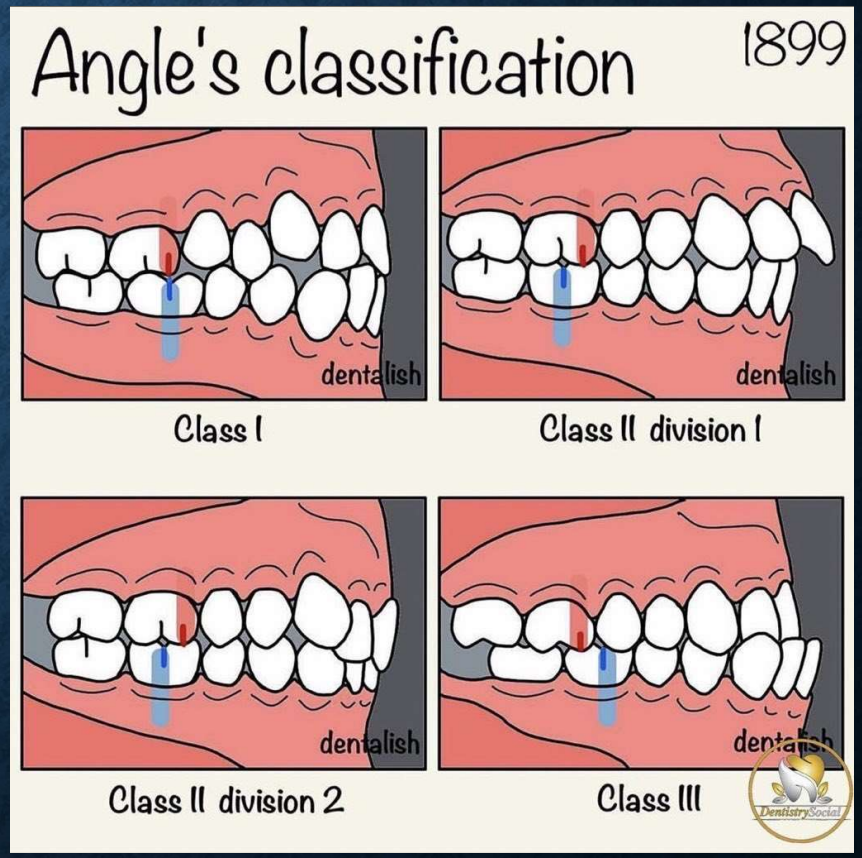

DEVELOPMENTAL DISTURBANCES OF LIPS AND PALATE

CONGENITAL LIP AND COMMISSURAL PITS AND FISTULAS

- malformations of the lips, often following a hereditary pattern
- in 75–80% of all cases of congenital labial fistulas, there is an associated cleft lip or cleft palate, or both. The association of pits of the lower lip and cleft lip and/or cleft palate, termed van der Woude's syndrome
- Commissural pits are an entity probably very closely related to lip pits, but occur at the lip commissures, lateral to the typical lip pits

ETIOLOGY

- Pits may result from notching of the lip at an early stage of development, with fixation of the tissue at the base of the notch,

or

- failure of complete union of the embryonic lateral sulci of the lip, which persist and ultimately develop into the typical pits

CLINICAL FEATURES

- A unilateral or bilateral depression or pit that occurs on the vermilion surface of either lip but far more commonly on the lower lip
- In some cases a sparse mucous secretion may exude from the base of this pit.
- The lip sometimes appears swollen, accentuating the appearance of the pits

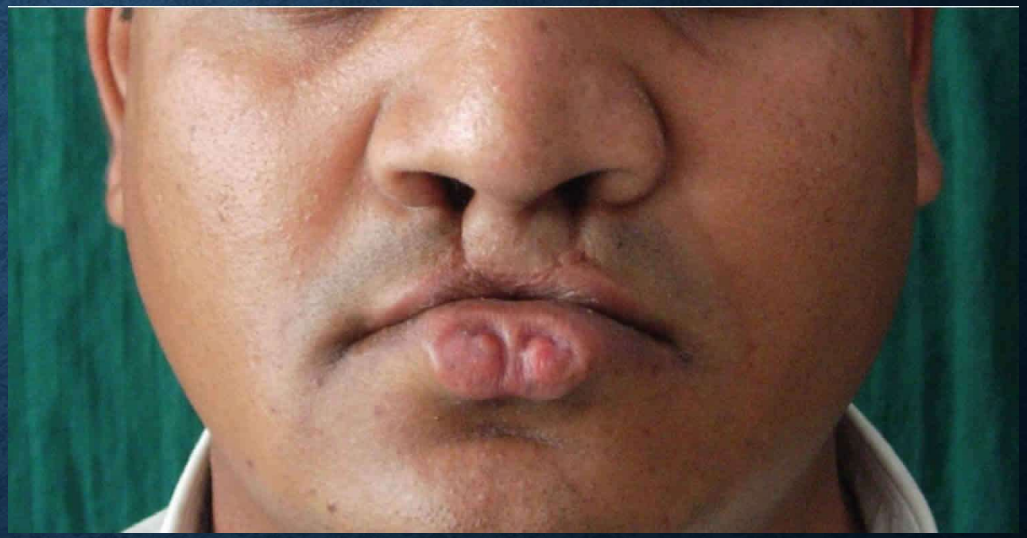

Treatment; Cosmetic correction if needed

VAN DER WOUDE'S SYNDROME (CLEFT LIP SYNDROME, LIP PIT SYNDROME, DIMPLED PAPILLAE OF THE LIP)

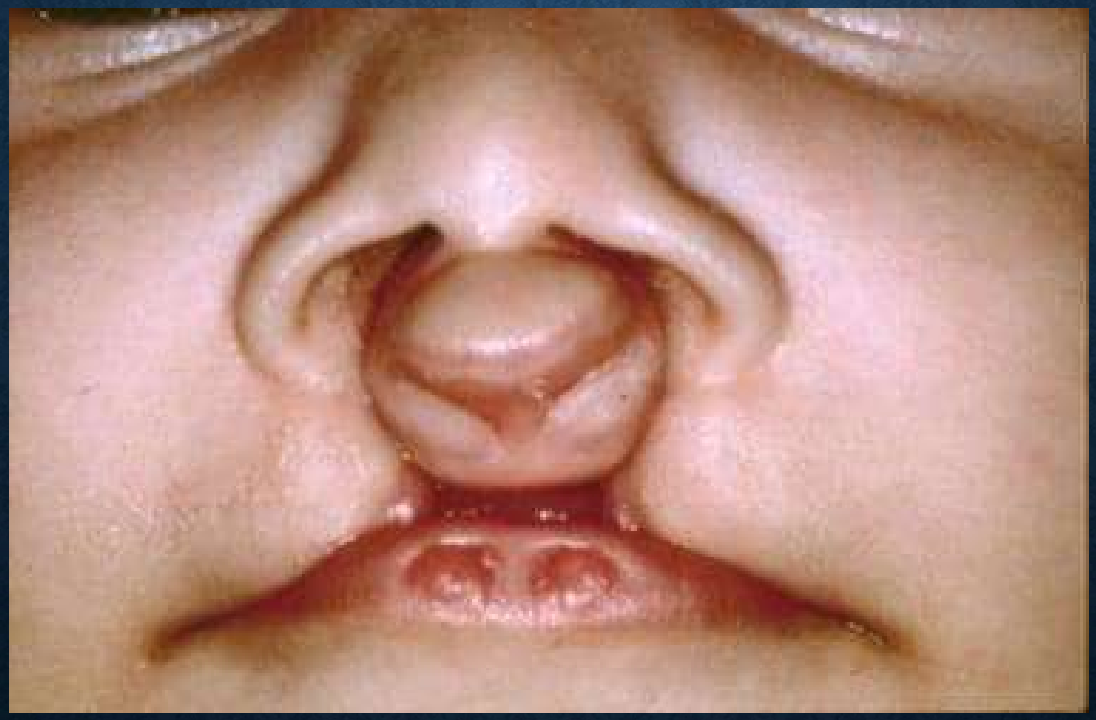

VAN DER WOUDE'S SYNDROME

- an autosomal dominant syndrome
- variable manifestations include lip pits alone, missing teeth, or isolated cleft lip and palate of varying degrees of severity

ETIOLOGY

- abnormal fusion of the palate and lips, at days 30–50 postconception.
- can be caused by deletions in chromosome band 1q32

CLINICAL FEATURES

- affects about 1 in 100,000–200,000 people. About 1–2% of patients with cleft lip or palate have van der Woude syndrome.
- Submucous cleft palate is common
- The pits are usually medial, on the vermilion portion of the lower lip.
- These pits are often associated with accessory salivary glands that empty into the pits, sometimes leading to embarrassing visible discharge
- Affected individuals may have maxillary hypodontia; missing maxillary incisors or missing premolars

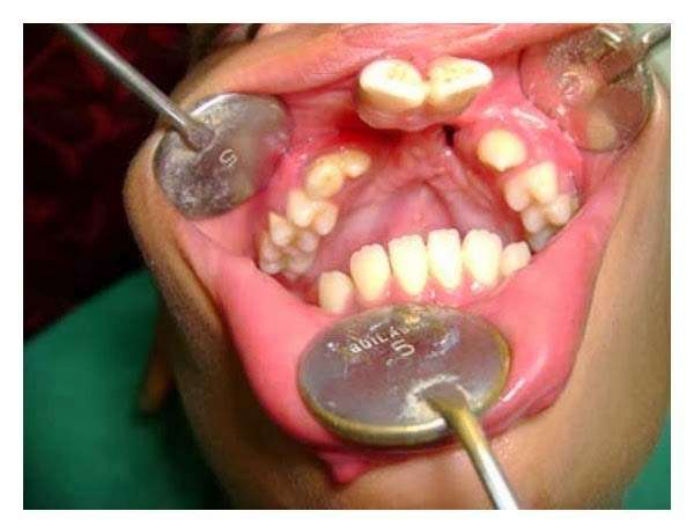

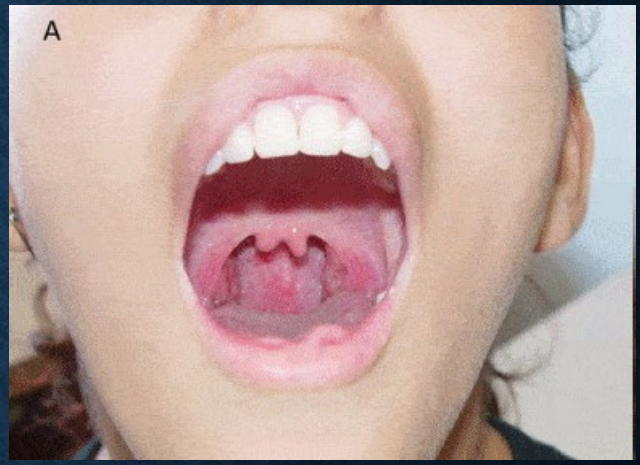
A

EXTRAORAL MANIFESTATIONS

- rare but include limb anomalies, popliteal webs, and brain abnormalities
- congenital heart defects, and Hirschsprung disease have also been reported

Treatment

- Examination and genetic counseling
- Surgical repair of the cleft lip and palate or other anomalies