DEVELOPMENTAL DISTURBANCES

Dr manasi kale

CHEILITIS GLANDULARIS (ACTINIC CHEILITIS)

- Progressive enlargement and eversion of the lower labial mucosa that results in obliteration of the mucosal-vermilion interface
- The delicate labial mucous membrane is secondarily altered by environmental influences, leading to erosion, ulceration, and crusting. Most significantly, susceptibility to actinic damage is increased.
- Therefore, CG can be considered a potential predisposing factor for the development of actinic cheilitis and squamous cell carcinoma.

ETIOLOGY

- Evolves in response to one or more diverse sources of chronic irritation.
- Lip enlargement is attributable to inflammation, hyperemia, edema, and fibrosis.
- Surface keratosis, erosion, and crusting develop consequent to longstanding actinic exposure, unusual repeated manipulations that include self-inflicted biting or other factitial trauma, excessive wetting from compulsive licking, drying (sometimes associated with mouth-breathing, atopy, eczema, and asthma), and any other repeated stimulus that could serve as a chronic aggravating factor.

CLINICAL FEATURES

- Patients typically present for diagnostic consultation within 3–12 months of onset.
- Asymptomatic lip swelling initially occurs with clear viscous secretion expressible from dilated ductal openings on the mucosal surface.
- A burning discomfort or a sensation of rawness.
- CG affects the lower lip almost exclusively.

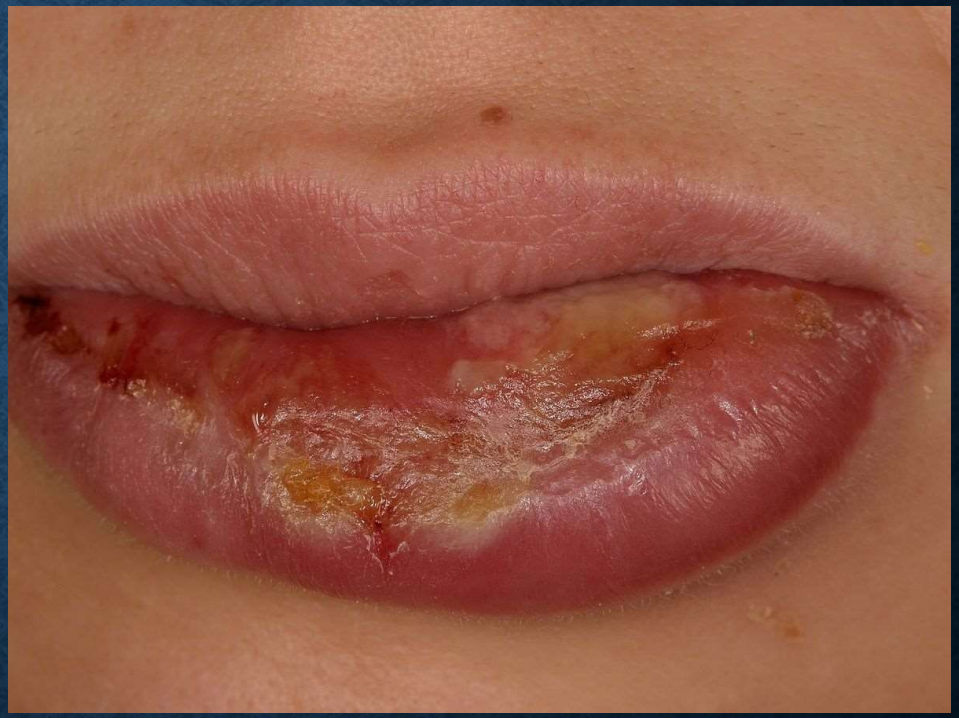

- Application of gentle pressure can elicit mucopurulent exudate.
- CG has been associated with a heightened risk for the development of squamous cell carcinoma.
- In many cases, dysplastic (premalignant) surface epithelial change is evident, and frank carcinomas have been reported in 18–35% of cases
- The disorder appears to favor adult males.
- most frequently occurs between the fourth and seventh decades of life
- The risk of dysplasia and carcinoma increases with age, especially in fair-skinned individuals with sun-damaged skin

CLASSIFICATION

- CG had historically been subclassified into three types, now believed to represent evolving stages in the severity of a single progressive disorder.
- • In the simple type, multiple, painless, papular surface lesions with central depressions and dilated canals are seen.
- • The superficial (suppurative) type (also referred to as Baelz disease) consists of painless, indurated swelling of the lip with shallow ulceration and crusting.
- • CG of the deep suppurative type (CG apostematosa, CG suppurativa profunda, myxadenitis labialis) comprises a deep-seated infection with formation of abscesses, sinus tracts and fistulas, and potential for scarring.
- The latter two types of CG have the highest association with dysplasia and carcinoma, respectively.

Differential diagnoses of this condition include

- actinic keratosis,
- atopic dermatitis,
- cheilitis granulomatosa (Miescher-Melkersson-Rosenthal syndrome),
- sarcoidosis
- squamous cell carcinoma.

Treatment: elimination of cause of chronic irritation, biopsy to rule out frank malignancy

CHEILITIS GRANULOMATOSA (MIESCHER-MELKERSSON-ROSENTHAL SYNDROME)

- chronic swelling of the lip due to granulomatous inflammation
- Miescher cheilitis is the term used when the granulomatous changes are confined to the lip. Miescher cheilitis is generally regarded as a monosymptomatic form of the Melkersson-Rosenthal syndrome
- Melkersson-Rosenthal syndrome is the term used when cheilitis occurs with facial palsy and plicated tongue.
- Melkersson-Rosenthal syndrome is occasionally a manifestation of Crohn's disease or orofacial granulomatosis.


Melkersson-Rosenthal Syndrome
Recurrent facial paralysis
Swelling of Lips
Fissured tongue

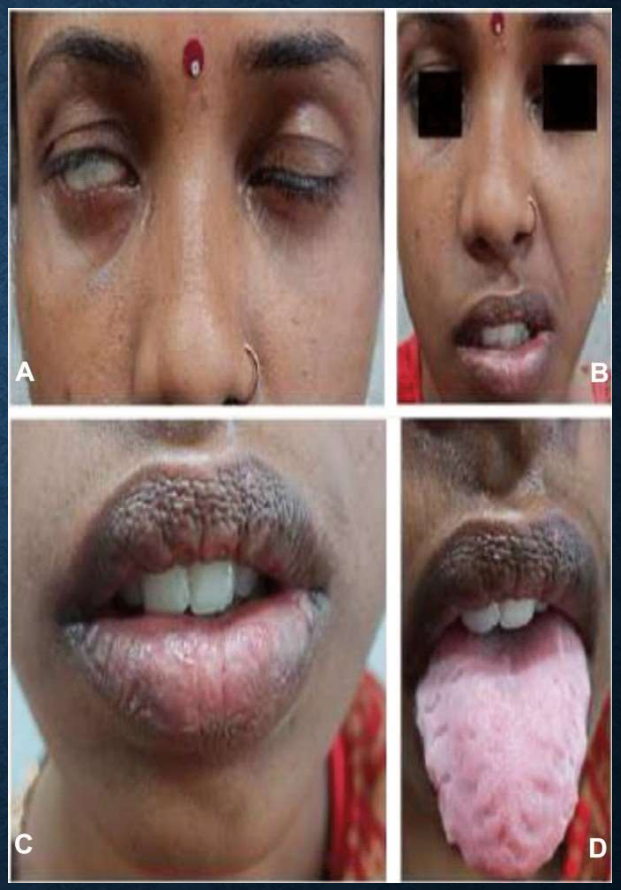
A
B
C
D

ETIOLOGY

- A genetic predisposition may exist in Melkersson-Rosenthal syndrome
- Dietary or other antigens are the most common identified causes of orofacial granulomatosis.
- Contact antigens are sometimes implicated.

CLINICAL FEATURES

- Cheilitis granulomatosa is episodic with nontender swelling and enlargement of one or both lips
- The first episode of edema typically subsides completely in hours or days. After recurrent attacks, swelling may persist and slowly increase in degree, eventually becoming permanent.
- Recurrences can range from days to years. Attacks sometimes are accompanied by fever and mild constitutional symptoms (e.g. headache, visual disturbance).

- The upper lip is involved slightly more often than the lower lip
- The earliest manifestation is sudden diffuse or occasionally nodular swellings of the lip
- the enlarged lip appears cracked and fissured with reddish brown discoloration and scaling. The fissured lip becomes painful and eventually acquires the consistency of firm rubber

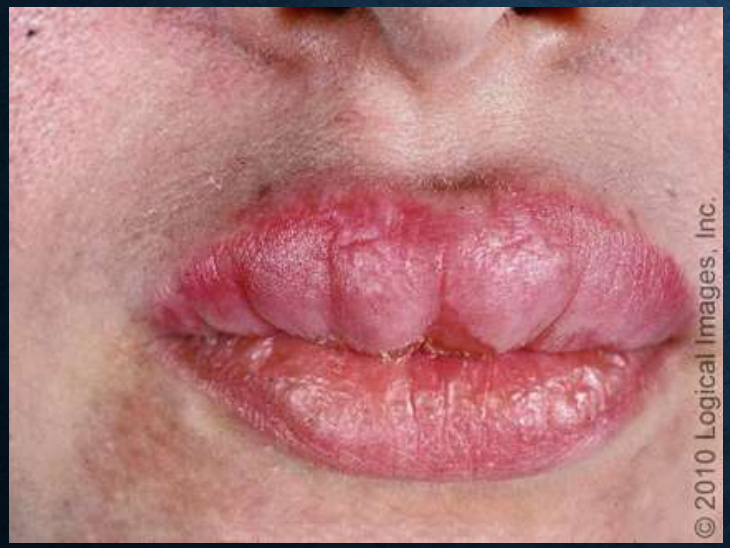

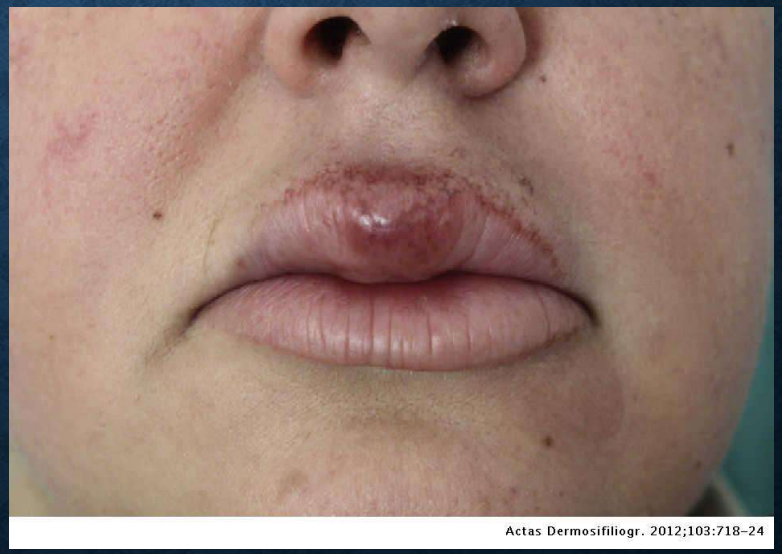

- Regional lymph nodes are enlarged (usually minimally) in 50% of patients. A fissured or plicated tongue is seen in 20–40% of patients. Its presence from birth (in some patients) may indicate a genetic susceptibility.
- Patients may lose the sense of taste and have decreased salivary gland secretion.
- Facial palsy of the lower motor-neuron type occurs in about 30% of patients
- There is no racial and sexual predilection.
- The age of onset is usually young adulthood.

DIFFERENTIAL DIAGNOSIS

- Differential diagnoses include insect bites and sarcoidosis.
- Serum angiotensin-converting enzyme test, chest radiography or gallium or positron emission tomography (PET) scanning may be performed to help exclude sarcoidosis.
- Gastrointestinal tract endoscopy and radiography may be used to help exclude Crohn's disease.

HISTOLOGIC FEATURES

- chronic inflammatory cell infiltrate—particularly peri and para-vascular aggregations of lymphocytes, plasma cells, and histiocytes
- focal noncaseating granuloma formation with epithelioid cells and Langhans type giant cells.

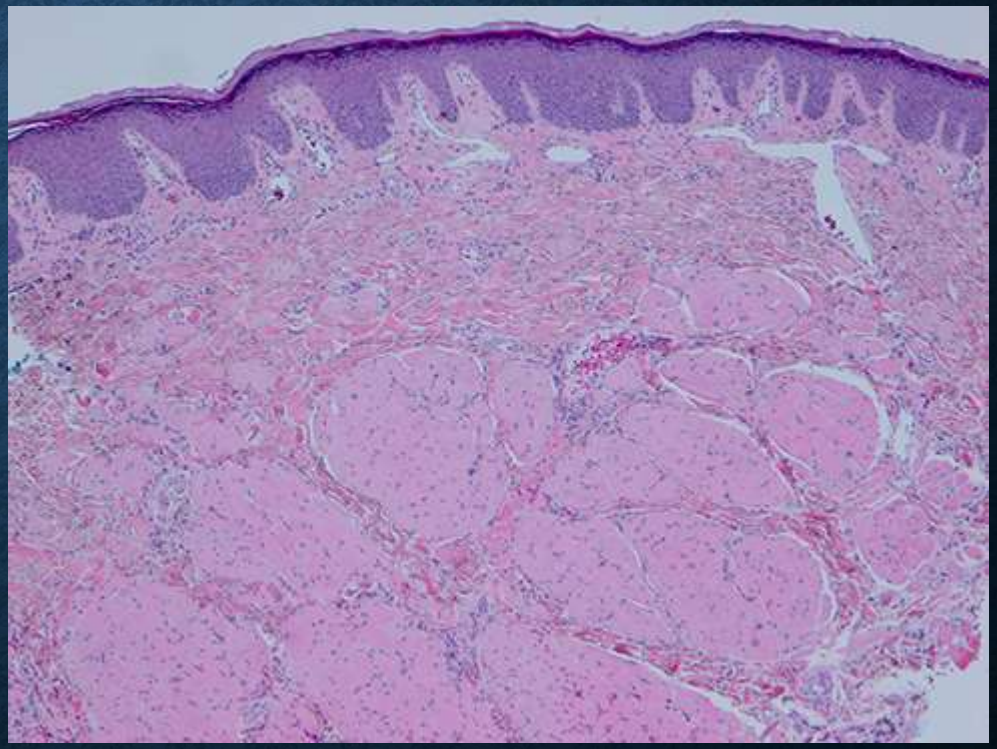

TREATMENT

- If found, avoidance of the implicated allergen is recommended.
- Conservatively managed by intralesional corticosteroid injections, nonsteroidal anti-inflammatory agents, mast cell stabilizers, clofazimine and tetracycline (used for anti-inflammatory activity).
- Surgery and radiation have been reported to be used.

HEREDITARY INTESTINAL POLYPOSIS SYNDROME

(Peutz-Jeghers syndrome, intestinal hamartomatous polyps in association with mucocutaneous melanocytic macules)

- an autosomal dominantly inherited disorder
- characterized by intestinal hamartomatous polyps in association with mucocutaneous melanocytic macules.
- A 15-fold elevated relative risk of developing cancer exists in this syndrome; cancer primarily is of the GI tract, including the pancreas and luminal organs, and of the female and male reproductive tracts and the lung.

ETIOLOGY

- The cause of the Peutz-Jeghers syndrome appears to be a germline mutation of the STK11 (serine threonine kinase 11) gene in most cases, located on band 19p13.3.
- Penetrance of the gene is variable, causing varied phenotypic manifestations among patients with Peutz-Jeghers syndrome (e.g. inconsistent number of polyps, differing presentation of the macules)

CLINICAL FEATURES

- Males=females
- The affected individuals usually have a positive family history of the Peutz-Jeghers syndrome.
- The principal causes of morbidity stem from the intestinal location of the polyps (i.e. small intestine, colon, stomach).
- The presenting complaints include repeated bouts of abdominal pain in patients younger than 25 years, unexplained intestinal bleeding in a young patient, or menstrual irregularities in females (due to hyperestrogenism from sex cord tumors with annular tubules).

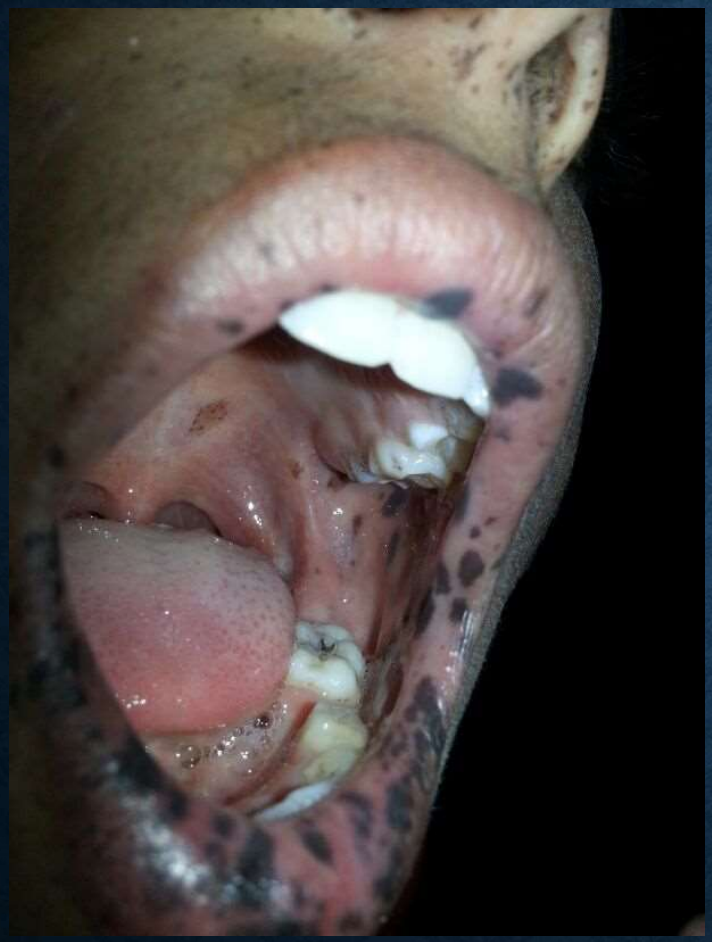

- Cutaneous pigmentation (1–5 mm macules) of the perioral region crossing the vermilion border, perinasal, and perioral areas is seen.
- This pigmentation may fade after puberty.
- Mucous membrane pigmentation primarily affects the buccal mucosa
- Other manifestations of this syndrome include precocious puberty, prolapse of tissue from the rectum, rectal mass (rectal polyp), testicular mass, gynecomastia and growth acceleration (due to Sertoli cell tumor).
- Surgical treatment for cancers detected by surveillance has been recommended.


ANY
QUESTIONS
?